

# Timeline in Pictures of Oral Aphthae as a Presenting Symptom for Behcet's Disease

Adam Ramsey, MD, Abdelkader Mallouk, MD, Amit Sharma, DO

Timothy Baxter, MD, Department of Family Medicine

## Introduction

Behcet's disease (BD) is a chronic, relapsing, inflammatory vascular disease with no pathognomonic test. Named after the Turkish scientist who first discovered it. Behcet's disease is believed to be an autoimmune over-reaction to either an infectious or environmental insult in a subset of patients that is genetically predisposed with a HLA-B51 genetic risk factor. BD typically presents in the third and fourth decade of life with no specific sex predilection.<sup>1,2,3</sup>

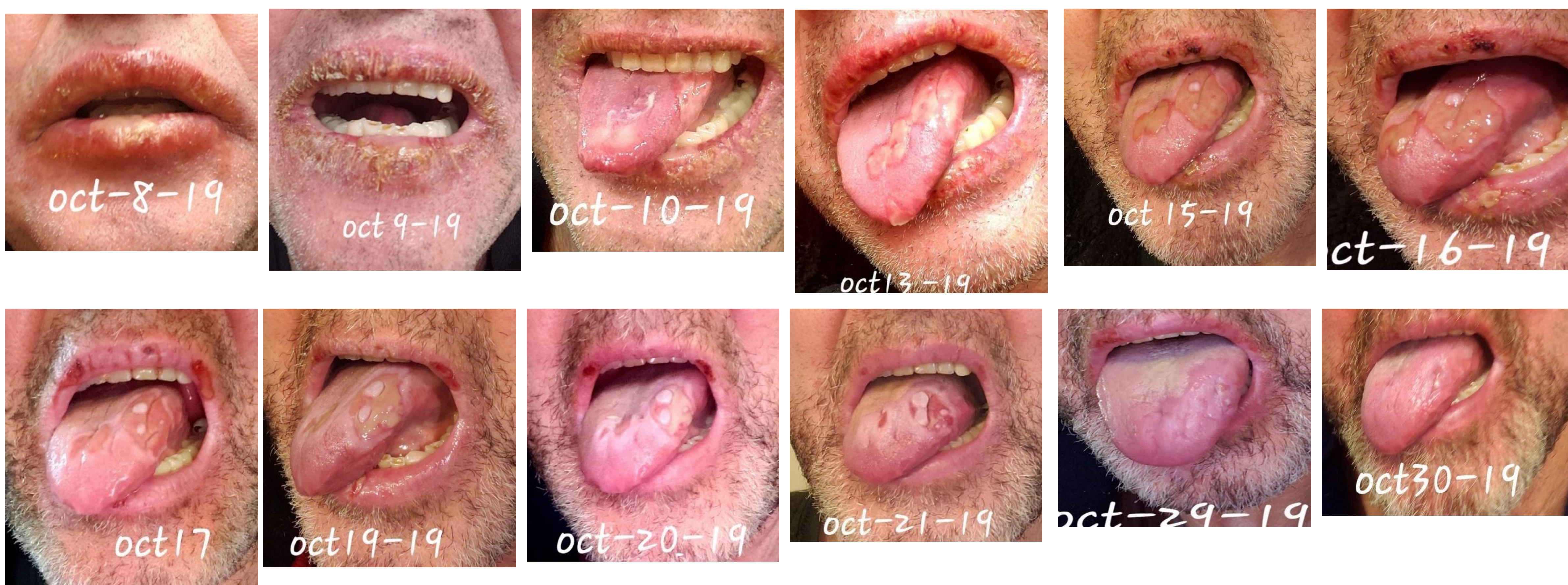
## Case Study

62-year old Turkish male who presented with history of the recurrent oral ulcers and penile ulcer (not pictured per patient's request).

- 10/7/19: The patient went to a walk-in clinic due to oral ulcers and a blister on his penis. The patient was told he most likely had Herpes and was prescribed Valacyclovir for treatment. However, the patient denied being sexually active for years and did not take the medication prescribed.
- 10/8/19 : woke up with back pain radiating to the right side of the mid-thoracic area for which he went to the ED; diagnosed with a kidney stone on CT imaging.
- 10/23/19 : ulcers healing on his lips and tongue.
- 10/24/19 : mild right thoracic pain; Kidney stones confirmed by CT scan.
- 10/30/19 : presented to office to establish care with one oral ulcer and was healing well.

The patient described two separate similar episodes of oral ulcerations over the previous year. The mouth ulcers started gradually in the buccal cavity, tongue, and lips without bleeding or discharge. There have been periods of complete healing and recurrences.

The chronological order of the development of his oral aphthae as shown in the illustrated pictures:



## Workup

<b>Vital Signs</b>	BP 120/82 mmHg	HR 68 beats per minute regular	RR was 17 breathes per minutes	O2 saturation was 96% on room air	
<b>Physical Examination</b>	General: 60 yo anxious male alert, oriented, and cooperative to exam.	HEENT: No oro-genital ulcerations, tongue swelling, eye lesions, normal visual acuity, normal visual fields, normal optic nerves and no signs of uveitis	Skin: No skin lesions or abnormalities at this time. No lymphadenopathy	Urogenital system: Normal male genitalia, no erythema, swelling, ulcerations, or discharge.	Cardio: RRR, no murmurs, rubs, or gallops.  Pulm: Normal Breath sounds in all lung fields.
<b>Laboratory Analysis</b>	Complete blood count: WBC 5.9 (10x3/uL) RBC 4.57 (10x6/uL) Hgb 14.6 G/DL Hct 42.8 % MCV 93.7 FL MCHC 34.1 G/DL MCH 32 PG Plt 253 (10x3/uL) RDW 14.5%	Basic Metabolic Panel: 139 Na mMOL/L 4.1 K+ mMOL/L 107 Cl mMOL/L 25 Carbon Dioxide mMOL/L 92 glucose MG/DL 19 BUN MG/DL 1.0 Cr MG/DL 9 Ca MG/DL	Immunological Tests: -Pathergy test (negative) -HLA-B27 antigen negative -Erythrocyte Sedimentation Rate (ESR) was 18MM/HR -C-Reactive Protein (CRP) was 1.03mg/L -Herpes Simplex Virus (HSV) Type 1&2 were undetected in the serum -Varicella-Zoster Virus (VZV) PCR was negative		

## Discussion

BD is a clinical diagnosis as defined by both the International Study Group for Behcet's Disease (ISGBD) and the International Criteria for BD (ICBD):

1. ISGBD requires the presence of recurrent oral aphthae ( $\geq 3$  times in 1 year) with at least two of the following criteria:
  - a. Recurrent genital aphthae (aphthous ulceration or scarring)
  - b. Eye lesions (retinal vasculitis, cells in vitreous, or uveitis)
  - c. Skin lesions (papulo-pustular lesions, pseudo-vasculitis, acneiform nodules, erythema nodosum)
  - d. Positive Pathergy test<sup>4</sup>.
2. ICBD classified BD as patient with  $\geq 4$  points based on criteria of<sup>6</sup>:
  - a. Ocular lesions, oral aphthosis and genital aphthosis are each assigned 2 points
  - b. Skin lesions, central nervous system involvement and vascular manifestations are 1 point each
  - c. The pathergy test, when used, is assigned 1 point.

The diagnosis of BD was made according to the ISGBD Criteria for this patient<sup>4</sup>. Based on the presence of recurrent oral aphthae ( $\geq 3$  times in 1 year) together with recurrent genital aphthae and the patient's self-reported skin lesions. The patient currently requires no treatment as his disease course is in remission. Treatment includes close monitoring with steroids or the combination of steroids and immunosuppressant drugs when vital organs are involved<sup>5</sup>.

## References

- 1 Yurdakul, S et al. 2004. Behcet syndrome. Curr. Opin. Rheumatol. 16: 38– 42
- 2 de Menthon, M et al. 2009. HLA-B51/B5 and the risk of Behcet's disease: a systematic review and meta-analysis of case-control genetic association studies. Arthritis Rheum. 61: 1287– 1296
- 3 Fietta, P. 2005. Behcet's disease: familial clustering and immunogenetics. Clin. Exp. Rheumatol. 23( 4 Suppl. 38): S96– S105.
- 4 International Study Group for Behcet's Disease. 1990. Criteria for diagnosis of Behcet's disease. International study group for Behcet's Disease. Lancet 335: 1078– 1080.
- 5 Kaklamani, V. G et al. 2001. Treatment of Behcet's disease—an update. Semin. Arthritis Rheum. 30: 299– 312.
- 6 J Eur Acad Dermatol Venereol. 2014 Mar;28(3):338-47. doi: 10.1111/jdv.12107. Epub 2013 Feb 26.